



The Journal of Threatened Taxa (JoTT) is dedicated to building evidence for conservation globally by publishing peer-reviewed articles online every month at a reasonably rapid rate at www.threatenedtaxa.org. All articles published in JoTT are registered under [Creative Commons Attribution 4.0 International License](https://creativecommons.org/licenses/by/4.0/) unless otherwise mentioned. JoTT allows unrestricted use, reproduction, and distribution of articles in any medium by providing adequate credit to the author(s) and the source of publication.

Journal of Threatened Taxa

Building evidence for conservation globally

www.threatenedtaxa.org

ISSN 0974-7907 (Online) | ISSN 0974-7893 (Print)

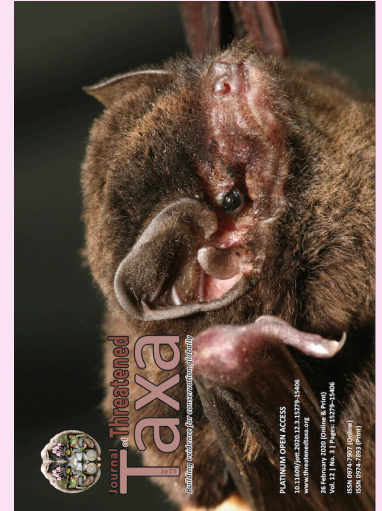REVIEW

RAMIFICATIONS OF REPRODUCTIVE DISEASES ON THE RECOVERY OF THE SUMATRAN RHINOCEROS *DICERORHINUS SUMATRENSIS* (MAMMALIA: PERISSODACTYLA: RHINOCEROTIDAE)

Nan E. Schaffer, Muhammad Agil & Zainal Z. Zainuddin

26 February 2020 | Vol. 12 | No. 3 | Pages: 15279–15288

DOI: 10.11609/jott.5390.12.3.15279-15288



For Focus, Scope, Aims, Policies, and Guidelines visit <https://threatenedtaxa.org/index.php/JoTT/about/editorialPolicies#custom-0>

For Article Submission Guidelines, visit <https://threatenedtaxa.org/index.php/JoTT/about/submissions#onlineSubmissions>

For Policies against Scientific Misconduct, visit <https://threatenedtaxa.org/index.php/JoTT/about/editorialPolicies#custom-2>

For reprints, contact <ravi@threatenedtaxa.org>

The opinions expressed by the authors do not reflect the views of the Journal of Threatened Taxa, Wildlife Information Liaison Development Society, Zoo Outreach Organization, or any of the partners. The journal, the publisher, the host, and the partners are not responsible for the accuracy of the political boundaries shown in the maps by the authors.

Member



Publisher & Host





Ramifications of reproductive diseases on the recovery of the Sumatran Rhinoceros *Dicerorhinus sumatrensis* (Mammalia: Perissodactyla: Rhinocerotidae)

Nan E. Schaffer¹ , Muhammad Agil²  & Zainal Z. Zainuddin³ 

¹SOS Rhino; IUCN/SSC Asian Rhino Specialist Group, 2414 Tracy Place, NW, Washington, D.C., USA.

²Department of Clinic, Reproduction and Pathology, Faculty of Veterinary Medicine, Bogor Agricultural University; IUCN/SSC Asian Rhino Specialist Group, Jl. Agatis, Kampus IPB Dramaga, Bogor 16680, Indonesia.

³Borneo Rhino Alliance; IUCN/SSC Asian Rhino Specialist Group, c/o Fakulti Sains Dan Sumbang Alam, Jalan UMS, 88400 Kota Kinabalu, Malaysia.

¹nan@sosrhino.org (corresponding author), ²rhinogil@gmail.com, ³zainalz.bora@gmail.com

Abstract: The Sumatran Rhinoceros *Dicerorhinus sumatrensis* is on the edge of extinction. The decline of this species was initially attributed to poaching and habitat loss, but evidence presented here indicates that reproductive failure has also been a significant cause of loss, and continues to affect wild populations. Indonesia's remaining populations of Sumatran Rhino are small and scattered, with limited access to breeding opportunities with unrelated mates. This leaves them subject to inbreeding and isolation-induced infertility, linked to fertility problems analyzed here. Sumatran Rhino females in captivity showed high rates (>70%) of reproductive pathology and/or problems with conception, which has significantly hindered the breeding program. Technological advances enabling examination immediately after capture revealed similarly high rates and types of reproductive problems in individuals from wild populations. The last seven Sumatran Rhino females captured were from areas with small declining populations, and six had reproductive problems. Going forward, capturing similarly compromised animals will take up valuable space and resources needed for fertile animals. The high risk of infertility and difficulty of treating underlying conditions, coupled with the decreasing number of remaining animals, means that the success of efforts to build a viable captive population will depend upon utilizing fertile animals and applying assisted reproductive techniques. Decades of exhaustive in situ surveys have not provided information relevant to population management or to ascertaining the fertility status of individual animals. Thus the first priority should be the capture of individuals as new founders from areas with the highest likelihood of containing fertile rhinos, indicated by recent camera trap photos of mothers with offspring. In Sumatra these areas include Way Kambas and parts of the Leuser ecosystem.

Keywords: Extinction, isolation-induced infertility, pathology, reproduction.

Editor: Anonymity requested.

Date of publication: 26 February 2020 (online & print)

Citation: Schaffer, N.E., M. Agil & Z.Z. Zainuddin (2020). Ramifications of reproductive diseases on the recovery of the Sumatran Rhinoceros *Dicerorhinus sumatrensis* (Mammalia: Perissodactyla: Rhinocerotidae). *Journal of Threatened Taxa* 12(3): 15279–15288. <https://doi.org/10.11609/jott.5390.12.3.15279-15288>

Copyright: © Schaffer et al. 2020. Creative Commons Attribution 4.0 International License. JoTT allows unrestricted use, reproduction, and distribution of this article in any medium by providing adequate credit to the author(s) and the source of publication.

Funding: SOS Rhino.

Competing interests: The authors declare no competing interests.

For **Author details**, **Author contribution** & **Bahasa Indonesia abstract** see end of this article.

Acknowledgements: Authors would like to acknowledge the multitude of keepers, caretakers and animal managers that made this work possible.



INTRODUCTION

The global population of Sumatran Rhinoceros *Dicerorhinus sumatrensis* was estimated at less than 100 individuals at the Sumatran Rhino Crisis Summit of 2013. For decades, the persistent decline has been attributed to uncontrolled poaching and habitat loss. Evidence presented here, however, indicates that reproductive failure (previously only associated with captivity) is an important factor in the continued decline of this species. The prevalence of reproductive problems across time and landscapes indicate a need to understand the scope and nature of this failure for successful recovery.

Between 1984 and 1995, a total of 41 Sumatran Rhinos were captured in Indonesia (Sumatra) and Malaysia (Peninsular and Sabah) (Rookmaaker 1998). The majority of males and females were placed in breeding facilities in each range country; three were moved to the United Kingdom and seven to the United States. At that time, the husbandry of this species was poorly understood and insufficient knowledge about diet, habitat, social structure, mating behavior, and reproduction hampered breeding efforts. Introductions of males and females often led to violent responses. These husbandry gaps resulted in significant losses in the initial captive population. Improvements in diet and behavioral management addressed some of these challenges, yet despite breeding, females were not producing offspring. With the advent of ultrasound in the 1990s, factors inhibiting conception were revealed (Schaffer et al. 1994) (Image 1). The high rate of pathologic abnormalities observed in the reproductive tracts of female rhinos from both Indonesia and Malaysia was initially presented at the 1999 Asian Rhino Specialist Group Meeting, and published shortly thereafter (Schaffer et al. 2002). In addition, pregnancy failure was linked to early embryonic death (Roth et al. 2001).

In early 2001, examination of a poached female in Sabah, Malaysia signaled that the problem was not exclusive to captivity (Image 2). In 2011 and 2014, two more females examined immediately after capture from the same geographic area in Sabah presented with extreme pathologic conditions (Fiuza et al. 2015; Schaffer 2018). The Sumatran Rhino was declared extinct in the rainforests in Malaysia in 2015. This trend will have serious implications for the success of Indonesia's 2018 Emergency Action Plan to build a productive captive population with the last Sumatran Rhinos, as set forth below.



Image 1. Analysis of reproduction in the first captive females was hampered by the lack of portable ultrasound machines. Pictured is Dr. Nan Schaffer with an early prototype in 1998. © SOS Rhino.

RESULTS

This paper is based on records of female Sumatran Rhinos captured or poached from various sites in Indonesia and Malaysia between 1984 and 2018. Available records for husbandry reports, laboratory results, histology, ultrasound images, and reproductive tract examination were compiled by Schaffer (2018). Source data and additional details on individual animals are available on the Rhino Resource Center website. A summary of the data is provided in Table 1, which includes animal identification, approximate age, dates and location of capture, breeding facility location, date of death, whether the animal copulated, examination results, and name of examiner. Age of adults, parous status, and relatedness were unknown with the exception of one genetically related breeding pair (Morales et al. 1997). Despite wide variability in parameters, the type of reproductive diseases were similar among individuals, and the rate of disease occurrence was high

Table 1. Details of the female Sumatran rhinoceros *Dicerorhinus sumatrensis* captured between 1984 and 2018 in Peninsula Malaysia; Sabah, Borneo, East Malaysia; Sumatra, Indonesia and Kalimantan, Borneo, Indonesia. The information includes (where available) date of capture, date of death, given name, facility where kept, approximate age at time of capture, and presence or absence of pathologies, method used and name of examiner. The table includes data on 3 females born in captivity, as well as data on a 2001 poached female found in Sabah.

Stud Book #	Capture location	Capture date	Name	Age at capture	Captive facilities	Date of death	Evidence of copulation	Evidence of pathology date recorded	Method	Examiner
01	Selangor, Malaysia	30.iv.1984	Jeram	Adult	Melaka, Malaysia	10.vii.2002	Yes	Uterine Tumors & Cysts (1991)	Ultrasound	N. Schaffer
03	Malaysia	18.iv.1985	Melintang	N/A	Melaka, Malaysia & Bangkok, Thailand	23.xi.1986	Unknown	No Records		
05	Torgamba, Indonesia	23.i.1986	Riau	Adult	Capture Site	23.i.1986	Unknown	No Records		
07	Johor, Malaysia	10.ii.1986	Rima	Adult	Melaka, Malaysia	12.iv.2003	Yes	Birthed SB15 (1987); Cysts (2001)	Ultrasound	R. Radcliffe
10	Torgamba, Indonesia	22.vi.1986	Subur	Adult	Port Lympne, UK	29.x.1986	No	Uterine Leiomyoma	Histology	C. Furley
11	Selangor, Malaysia	6.vii.1986	Julia	Adult	Melaka, Malaysia	15.xii.1989	No	No Pathology	Gross Pathology	Z. Zahari
12	Malaysia	9.ix.1986	Dusun	~10 Yrs.	Melaka, Malaysia, Jakarta & Way Kambas, Indonesia	7.ii.2001	Yes	Chronic Lactation (1992-2001); Irregular Uterus & Ovaries	Ultrasound Histology	N. Schaffer M. Agil
13	Selangor, Malaysia	25.ii.1987	Panjang	~5 Yrs.	Melaka, Malaysia	9.xi.2003	Yes	Uterine Cysts (1991); Tumors (2002)	Ultrasound	N. Schaffer R. Radcliffe
15	Captive Born to SB07 in Melaka, Malaysia	23.v.1987	Minah	N/A	Melaka, Malaysia	16.xi.2003 15YRS.	Yes	Cysts (2001)	Ultrasound	R. Radcliffe
16	Selangor, Malaysia	1.vii.1987	Seridelima	~7 Yrs.	Melaka, Malaysia	23.ix.1988	No	No Pathology	Gross Pathology	Z. Zahari
18	Torgamba, Indonesia	21.vii.1987	Meranti	Adult	Port Lympne, UK	4.xi.1994	No	Uterine Leiomyoma (noted before death in 1994)	Histology	C. Furley
19	Malaysia	26.viii.1987	Mas Merah	~8 Yrs.	Melaka, Malaysia	17.xi.2003	Yes	Few, Small Uterine Tumors & cysts (1991) Same Findings (2001)	Ultrasound	N. Schaffer R. Radcliffe
22	Torgamba, Indonesia	8.vii.1988	Dalu	Adult	Taman Safari, Indonesia	27.vi.1993	Yes	Multiple Corpus Luteum; Enlarged Uterus (1993)	Histology	N. Schaffer M. Agil
23	Pahang, Malaysia	11.vii.1988	Seputih	~10 Yrs.	Melaka, Malaysia	28.x.2003	Yes	Uterine Cysts (1991); Large Tumor (1998); Tumors, Cysts (2002)	Ultrasound	N. Schaffer R. Radcliffe
24	Bengkulu, Indonesia	22.vii.1988	Mahato	Juvenile	Los Angeles & Gindimati, USA	10.v.1992	No	Immature Reproductive Tract (1992)	Gross Pathology	N. Schaffer
25	Bengkulu, Indonesia	24.vii.1988	Barakas	~12 Yrs.	San Diego, USA	22.ii.1995	No	Cystic endometrial hyperplasia (1995)	Histology	L. Lowentine
26	Lahad Datu, Malaysia	22.iv.1989	Lun Parai	~6 Yrs.	Sepiok, Sabah, Malaysia	23.viii.2000	Yes	Uterine Tumor and cysts (1998) Leiomyoma (2001)	Ultrasound Histology	N. Schaffer
27	Bengkulu, Indonesia	26.viii.1989	Rapunzel	~6 Yrs.	Los Angeles & New York, USA	22.xii.2005	No	Uterine Tumors and cysts (1994)	Ultrasound	N. Schaffer
29	Bengkulu, Indonesia	6.iii.1991	Emi	~1 Yr.	Los Angeles & Cincinnati, USA	5.ix.2009	Yes	5 Abortions (1998 – 2001); 3 births (2001, 2004, 2007); Cysts (resolved) (2002)	Ultrasound	T. Roth
32	Bengkulu, Indonesia	17.v.1991	Bina	~3 Yrs.	Taman Safari & Way Kambas, Indonesia		Yes	Post productive (2010); Few cysts (2014); Cycling (2019)?	Ultrasound Ultrasound	N. Schaffer T. Roth
33	Bengkulu, Indonesia	12.vi.1991	Rami	~8 Yrs.	San Diego, USA	25.v.1992	Unknown	No Records		L. Lowentine
34	Bengkulu, Indonesia	17.i.1992	Wiwien	~4 Yrs.	Surabaya, Indonesia	12.xi.1996	Unknown	No Records		
40	Tabin, Malaysia	17.vi.1994	Gologob	Adult	Sepiok, Sabah, Malaysia	11.i.2014	Yes	Few uterine cysts (1998); more cysts (2004) Post productive (2010)	Ultrasound Ultrasound	N. Schaffer P. Kretzschmar

Stud Book #	Capture location	Capture date	Name	Age at capture	Captive facilities	Date of death	Evidence of copulation	Evidence of pathology date recorded	Method	Examiner
	Poached Animal Sabah, Malaysia	2001	Female	Adult	Wild, Sabah	N/A	No	Cysts and 3 Leiomyoma (2001)	Histology	N. Schaffer
43	Captive Born to (SB29 +28) Cincinnati, USA	30.vii.2004	Suci	N/A	Cincinnati, USA	30.iii.2014	No	Immature		
45	Bukit Barisan Selatan, Indonesia	30.ix.2005	Rosa	~3 YRS.	Way Kambas, Indonesia		Yes	Tumors & Cysts 5 years post cycling (2015); Early Embryo loss (2018)	Ultrasound	T. Roth
46	Way Kambas, Indonesia	20.ix.2005	Ratu	~5 YRS.	Way Kambas, Indonesia		Yes	2 Abortions (2009–2010); 2 Births (2012, 2016)	Ultrasound	T. Roth
51	Tabin, Malaysia	18.xii.2011	Puntung	Adult	Sabah, Malaysia	15.vi.2017	No	Multiple Uterine Cysts (2012)	Ultrasound	Z. Zahari
57	Danum Valley, Malaysia	10.iii.2014	Iman	Adult	Danum Valley, Sabah	16.xi.2019	No	Uterine Tumors and Cysts (2014)	Ultrasound	Z. Zahari
58	Captive Born to (SB42 +46) Way Kambas, Indonesia	12.v.2016	Delliah	N/A	Way Kambas, Indonesia		No	Immature		
	Kutai Barat, Indonesia	12.iii.2016	Najaq	Old	Died at Capture Site	5.iv.2016	No	No pathology, but ovaries and uterus quiescent	Gross Pathology	M. Agil
	West Kutai, Indonesia	25.xi.2018	Pahu	Old	Kelian (Kalimantan) Indonesia		No	Ovarian Tumor (2019)	Ultrasound	M. Agil

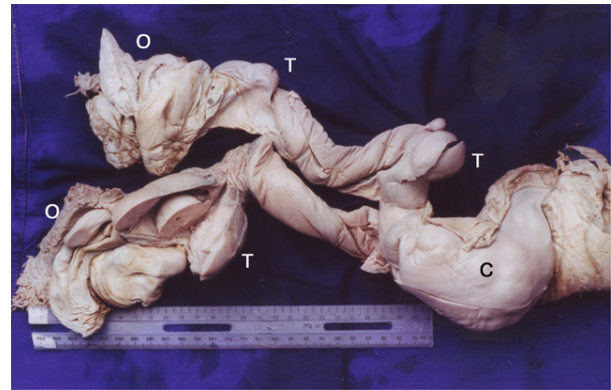


Image 2. A poached wild animal's reproductive tract has extensive pathology. O (ovary), C (cervix), T (tumor). © Nan Schaffer.

in all geographic areas of origin and all geographic areas of captivity, including breeding sanctuaries in Indonesia (Sumatra and Kalimantan), Malaysia (Peninsular and Sabah), and all zoos and reserves in the United States and United Kingdom.

Reproductive analysis of captured animals prior to 2000 was sporadic. Hampered by a lack of equipment and limited expertise, only three animals were examined after death at capture. Thus, potential disease processes and conditions affecting reproduction such as early embryo death remained unidentified and unrecorded until monitoring was implemented on a consistent basis. By 2000, a broader base of available expertise, protocols and reporting standards ensured that the last seven females captured: a poached female, Ratu, Rosa, Puntung, Iman, Najaq, and Pahu were examined and reproductively monitored from the beginning of their captive status. Since 1984, of the 32 females brought into captivity, analyses of the reproductive tract were available for 25 because three animals had not reached maturity and four had no records. Out of 25, 22 individuals (88%) presented with some kind of reproductive disease. Out of the 22 animals, 14 females did not conceive despite copulating a few to several times and eight females were without access to a breeding male. Females copulated even if they had pathology.

Cysts and Tumors

Uterine cysts and tumors were the most frequently documented reproductive problems (42%), and were primarily noted on ultrasound evaluation. Gross visualization of intraluminal cysts was noted in a female that died in captivity in 2000 (Lun Parai). A female poached in 2001 had numerous tumors and cysts. Histology reports regarding the endometrium were

available for only two females: endometrial edema (Dalu) and cystic endometrial hyperplasia (Barakas).

Histopathology on the uterine masses of six animals confirmed leiomyoma. The ultrasound images of these tumors were consistent with signs of smooth muscle fibroma (dense, round circumscribed) and firm on palpation. Tumors occurred in three obviously older animals (Rapunzel, Jeram, Subur), five adults (Lun Parai, Meranti, Mas Merah, Iman, and a poached female), and one young female (Rosa). The tumors present in Mas Merah had not changed when examined 10 years after the original exam. Two animals Panjang and Seputih both presented with only a few cysts when initially examined. Follow-up exams 10 years later revealed that each had developed tumors in the both the vagina and uterus. Abnormalities were also observed in younger animals. Minah, who was born in captivity, had cysts by 14 years of age, but this may have been due to her exposure to exogenous hormones. Another juvenile, Rosa, began cycling in 2010 and began to develop pathology in 2015 (Ferawati et al. 2018).

Early Embryo Death

When ultrasound was finally applied consistently enough to monitor for signs of pregnancy, animals were found to be losing embryos. Three monitored animals (Emi, Ratu and Rosa) entered captivity young, but subsequently had difficulty maintaining pregnancy. First time pregnancies might account for first time abortions, but it was unclear why multiple spontaneous abortions (Emi 5; Ratu 2) occurred thereafter. Rosa was reluctant to breed when she began to cycle and a few years later she developed significant pathology and is currently losing embryos.

Unusual Findings

Two females in residential zoos, Dalu (Taman Safari, Bogor, Indonesia) and Dusun (Melaka, Malaysia and Ragunan, Jakarta, Indonesia) had unusual histories and pathological findings. Dalu's reproductive tract had multiple corpus luteum and a significantly enlarged uterus that revealed edema with hemosiderin without evidence of infection. After breeding, Dusun lactated for nine years before her death. Findings on necropsy noted chronic cystic kidney disease and darkening of multiple organs, including the skin, suggesting hemosiderosis.

Infection

No signs of infections were identified in the few histological reports provided. One female (Panjang) displayed possible infectious processes such as fluid

in the lumen of the uterus. Iman demonstrated a large tumor and pyometra that cultured as alpha and beta hemolytic streptococcus at the time of capture. She subsequently died when the large tumor finally interfered with her urinary tract.

DISCUSSION

Infections of the uterus were rarely observed in the Sumatran Rhino, which is consistent with findings reported in other species of rhinoceros by Hermes & Hildebrandt (2011). Nutritional factors apparently influenced the development of abnormal conditions in two animals. The predominant signs of reproductive failure identified in this species are uterine cysts, uterine tumors, uterine hyperplasia, and early embryonic loss, all of which are indicative of hormonal imbalances. Hormonal imbalances can be associated with the factors of age, lack of parity, and the aberrant genetics inherent in non-producing (isolated) and inbred animals.

Nutrition

Although multiple corpora lutea can be a normal occurrence in horses and camelids, the greatly enlarged uterine endometrium in one rhinoceros and prolonged lactation in another indicated disease. The unusual conditions in both Dusun and Dalu occurred in the presence of hemosiderosis. Both of these animals were in residential zoo settings where proper foods were not readily available, and they died before nutritional requirements for this species were elucidated.

Effects on the reproductive system could have stemmed from direct deposits of iron into the reproductive organs of rhinos, a process that can eventually turn the endometrium dark brown (Nan Schaffer, pers. obs. 1992), or indirectly from iron deposition into organs such as the kidney that influence hormone levels. Kidney failure was the most commonly reported cause of death in the Sumatran Rhinoceros after gastrointestinal disease (Foose 1999).

An uncommon symptom of chronic kidney disease is galactorrhea whereby chronic nephritis results in a lack of clearance of the hormone prolactin (Hou et al. 1985). Dusun was the only animal to present with this syndrome, and she was also the only one that demonstrated signs of late pregnancy loss. The histology report on Barakas (San Diego Zoo) showed the multiple system-wide occurrence of hemosiderosis, which was also evident in this animal's cystic, hyperplastic endometrium.

The last two animals to die of hemosiderosis

were a breeding female (Emi) and her offspring (Suci) at the Cincinnati Zoo. The fact that their diets had been improved considerably over time may have relieved effects on the reproductive system. Deaths from iron overload have become rare as a result of the improved diet available in semi-wild sanctuaries located in Indonesia and no animals have succumbed to hemosiderosis since Suci's death in 2014.

Age

Cysts are most closely associated with age in horses, and are found in 22% of adult mares and 55% of older mares (Wolfsdorf 2002). Even though cysts seem to develop as rhinos aged, some apparently younger animals (Minah, Emi and Rosa) also developed cysts.

Tumors are associated with non-productive females (Hermes et al. 2004) and have been documented in rhinos as young as 15 years of age (Montali & Citino 1993). The fact that Rosa, a young non-productive Sumatran female, developed pathology five years after maturity is an ominous sign for animals in the wild that are unable to stay consistently pregnant. The progressive nature of the disease was also evident in Rosa, who initially had few cysts and then developed a tumor. This was observed in two additional non-productive animals, who progressed from having cysts to several tumors. The fact that there are fewer and fewer signs of offspring in many of the small, scattered remaining populations of the Sumatran Rhino may be an indication of development of this disease, which results in the loss of fertility.

Protection of Parity

In other species, parity may provide some protection from developing reproductive pathology (Parazzini et al. 1988; Hermes et al. 2004). The parous state of the Sumatran Rhino has been difficult to assess because the majority of animals were adult when captured and hymens were rarely checked when individuals entered captivity. Most reports of the condition of the hymen are connected with attempts to break the hymen of the female after the male had difficulty copulating with her. Parity was confirmed in only three animals.

Rima gave birth just after entering captivity, yet despite regular breeding thereafter, she did not become pregnant. The fact that she did not develop cysts until her later years, suggests that her pregnancy protected her from pathology.

High rates of pathology in females may occur because they were non-productive before they entered captivity and remained so afterwards.

Reduced Parity with Early Senescence

An analysis of reproductive events in the captive population of Sumatran Rhinoceros suggests that premature senescence occurs in non-productive females. Ordinarily in mammals, except for humans, reproductive life typically lasts up until the end of life. Three older animals had a long period wherein the ovaries were inactive before death: Jeram was post-productive for 10 years, Rapunzel for 10 years, and Gologob for four years. Bina has never conceived despite multiple attempts with one male and is presently reluctant to breed with new males, which may indicate beginning senescence. Premature senescence with high rates of reproductive pathology, termed "asymmetric reproductive ageing" in captive White and Indian Rhinoceroses, reduces the production of offspring in females that experience a prolonged lack of pregnancy (Hermes et al. 2004). Notably, pregnancy is common in herds of older White Rhinoceroses in the wild, suggesting that this may not be a problem in these herds (Kretzschmar, pers. comm. 2018). In the Sumatran Rhinoceros, among the last seven captured females five presented (soon after capture) with either pathology or as older animals with quiescent reproductive tracts suggesting they had reduced breeding opportunities in the wild.

Inbreeding Effects

Small populations often suffer the effects of inbreeding depression. Deleterious alleles may have been expressed in Sumatran Rhinoceros males and females which can predispose females to disease processes such as fibrous tumors (Medikare et al. 2011). The heritable component of hemosiderosis may have been demonstrated when Suci, an offspring from a pair of closely related parents, died from genetically related iron sensitivity (Morales et al. 1997). While Suci's brothers survived and became productive, she and her mother succumbed to hemosiderosis. Moreover, recessive alleles have been directly expressed as problematic reproductive morphologies, including an abnormal male penile skin attachments and intact "imperforate" hymens in two captive females that had their hymens manually broken before copulation could succeed (Filkins 1965; Tibary 2016).

Attempting to breed animals from highly inbred populations will severely compromise production. The effective number of breeders is now so low that recovery of genetic vigor will require careful genetic mixing. Therefore, infusion of genetic resources from animals in Kalimantan and the exchange of genetic resources between rhinos from the northern and southern areas

of Sumatra will be vital for this species survival.

Treatment

Only after females could be closely monitored within a captive setting could early pregnancy loss be diagnosed and treated with drugs that prevent embryo loss in other rhinoceros species (Berkeley et al. 1997; Roth et al. 2004). To date, all females that have delivered offspring in captivity have been medicated with progesterone supplements, as demonstrated by Schaffer et al. (1995).

Treatments become increasingly less successful the more pathology a female develops. Certain types of cysts are more problematic, but this cannot be confirmed without a biopsy. Though only one cystic endometrial hyperplasia has been reported, this condition may have been more common. Uterine biopsy could be a useful tool in elucidating the reproductive condition of individuals. Difficulties sampling the uterine tissue of larger species of rhinoceros have been overcome and access to the uterus of the Sumatran Rhino has been accomplished (Radcliffe et al. 2000; Hermes et al. 2009).

Extensive numbers of cysts and/or tumors will interfere with maintenance of pregnancy. In domestic horses, treatment of cysts involves mechanical intervention such as aspiration or hormonal removal. Procedural complications and reoccurrence of the cysts is common. To date, treatment of cysts in Sumatran Rhinos with extensive pathology has been unsuccessful and resulted in the return of cysts (Fiuza et al. 2015). Emi developed a few cysts between successful pregnancies, indicating it may be possible for females to achieve pregnancy when cysts are minimal. Although mares have achieved pregnancy with mild cases of only a few cysts, Panjang and Seputih were breeding with negligible cysts, but neither produced offspring. Unfortunately, like most animals captured during the 1980's and 1990's, it was impossible to determine whether or not uterine cysts interfered with embryos in these individuals. The monitoring of Rosa has revealed that she has developed cysts and a tumor. Embryos are also forming with breeding, but she is not maintaining her pregnancies despite progesterone treatments. Unlike Ratu and Emi whose healthy, pathology-free uteri responded successfully to progesterone treatments, Rosa is unlikely to become pregnant even with progesterone. Thus, Rosa's only chance to contribute to the recovery of this species is through the application of Advanced Reproductive Techniques.

Leiomyomas were the most common type of reproductive tumors in the rhinoceros (Montali & Citino 1993). Hermes & Hildebrandt (2011) described species

differences among rhinos in the typical location of tumors, in the reproductive tract. Indian Rhinos typically develop vaginal tumors, White Rhinos typically develop uterine tumors, and Sumatran Rhinos develop both. Early cases of uterine tumor removal were not successful in the Sumatran and Indian Rhinoceros (Klein et al. 1997; Foose 1999). Although a few vaginal tumors have been removed, there has not been a further attempt to remove uterine tumors thus far (Radcliffe 2003). Some hormone treatments show promise in shrinking these tumors (Hermes et al. 2016). Other treatment regimens useful for domestic animals have been explored for non-productive female Sumatran Rhinoceroses (Radcliffe 2003). Unfortunately, these animals died before treatment effects could be ascertained. Animals with pathology will be difficult and time consuming to recover.

Ramifications for Female Sumatran Rhinos

Reproductive problems prevalent in small, isolated, inbred populations of Sumatran Rhinos in captivity are also evident in animals in the wild. The first indication that pathology could be a problem in populations in the wild was observed in 1986 with the capture of the first animal in Indonesia. The discovery of tumors at the necropsy of this female within four months of entering captivity suggested that she developed the tumors before she was captured (Furley 1993). Early capture efforts focused on capturing "doomed" animals (Nardelli 2014), many of which had or later developed reproductive problems. The prevalence of reproductive problems in females, however, became evident in the wild after 2000 when animals were routinely examined immediately after capture. Since 2001, newly captured females have also been from "doomed" areas. Fertility problems have been pervasive in these "rescued" females. All seven of these female Sumatran Rhinos captured had reproductive problems: five had reproductive abnormalities that were observed immediately after capture, and early embryonic death was subsequently observed in two animals. A high rate of infertility is inherent in small inbred populations with isolated females, and it continues to interfere with the growth of captive and wild populations.

The existence of pathology in females suggests they have had few, if any, offspring in the wild, and indeed there is no evidence of births in the areas where rhinos have recently been captured in Sumatra (Bukit Barisan Selatan and Way Kambas National Parks) and Sabah (Tabin Wildlife Reserve and Danum Valley). These areas have seen precipitous drops in rhino populations. For example Way Kambas had 26–31 rhinos according to the

2015 population viability analysis (Miller et al. 2015), while recent observations indicate the population now numbers 4–9 rhinos (Marcellus Adi pers. comm. 2019). Areas with steadily declining populations and little evidence of offspring will continue to provide predominately reproductively compromised animals.

Credible demographic information about populations is nonexistent, except for the fact that they are disappearing. To date, no population assessment tool or combination of tools including surveys, camera-traps, and fecal DNA analyses has provided the critical fertility information required to manage this species in the wild. Camera-trap photographs of a few females with young can only provide information on where potentially fertile rhinos can be found; it does not define or confirm the ongoing viability of the current population or survival of the species. Realistic information applicable to the Sumatran Rhino should have been used for successful modeling of extinction outcomes for this species (Miller et al. 2015). For years we have had all the information we needed to show that the Sumatran Rhino in Indonesia can no longer be sustained in the wild, particularly in the face of mounting infertility and negative growth rates, even with the absence of poaching.

Fertile females are the determinant factor in the recovery of this Critically Endangered species (Kretzschmar et al. 2016). When numbers are critically low and the risk of infertility so high, the fertility status of every female rhinoceros must be ascertained and constantly monitored, which is not possible when the status of animals is unknown. Intensive management zones (IMZs) and/or intensive protection zones (IPZs) are not suitable for this cryptic rainforest species, because the information necessary for successful management cannot be obtained within such areas (Ahmad et al. 2013; Payne & Yoganand 2018). Although these management strategies may apply to the larger African and Asian rhinoceros populations, which can be observed, monitored and sampled at the individual level, these strategies are inappropriate and dangerously non-productive for the Sumatran Rhino (Image 3). The only way to determine the fertility status of an individual Sumatran Rhino is through direct, hands-on examination in a captive setting.

After 25 years of perfecting tools and techniques in captivity, the Sumatran Rhino Sanctuary (SRS) design in Way Kambas is currently the only option for successful reproductive management of Sumatran Rhinos. Only in this environment can the essential management information be obtained, and reproduction optimized. Fertility monitoring for this species requires confirming



Image 3. In contrast to decades of unreliable surveys, direct observation and analysis has been the only source of relevant information for productive management. © Nan Schaffer.

reproductive events by comparing ultrasound images with individual hormonal levels in feces or blood. Treatment protocols for pathology have been attempted but need further development (Radcliffe 2003). Simulation or inducement of pregnancy may be the only prevention (Roth 2006; Hermes & Hildebrandt 2011; Hermes et al. 2016; Roth et al. 2018). Females have been successfully assisted with the maintenance of their pregnancies, and offspring have resulted. Other techniques are evolving quickly to optimize production in this species (Galli et al. 2016) even though minimal and marginal genetic material has been available. As happened with the Northern White Rhino, soon there will be little genetic material left for preserving the last record of the Sumatran Rhino (Saragusty et al. 2016; Nardelli 2019). The success of a single genetically distinct union could revitalize this Critically Endangered species. None of these conditions will be identifiable or treatable while animals are in the wild. Time is running out for younger treatable animals, which without pregnancy are at risk of rapidly developing pathology, given that Rosa developed pathology in less than five years.

CONCLUSION

The critically low estimates of numbers in widely scattered populations of the Sumatran Rhino, coupled with the fact that both captive populations and animals caught from the wild are largely reproductively compromised, means that only a small number of reproductively viable animals may be left in the wild. In addition, the complete lack of relevant information, and in some cases wild extrapolations, on the status of animals makes addressing these problems in the

wild impossible. In light of these facts, building a new productive captive population by starting immediately with capturing viable, productive animals from the onset and optimizing their production is essential. Recovery and use of vital genetic materials must be accelerated before these resources are lost. Fertile animals must be the first priority for the few sanctuary spaces that are available. The best chance of obtaining fertile founders exists in the few clusters where females with young have been confirmed with recent camera-trap photos. These will also be the areas where females are at risk of fewer pregnancies, but may still be recoverable with treatment. Only two such areas have provided such evidence: Way Kambas National Park (Lampung, southern Sumatra) and certain areas of the Leuser ecosystem (Aceh, western Sumatra). They are the first focus areas for capturing viable females, before they, too, are lost.

REFERENCES

- Ahmad, A.H., J. Payne & Z.Z. Zainuddin (2013). Preventing the extinction of the Sumatran Rhinoceros. *Journal of Indonesian Natural History* 1: 11–22.
- Berkeley, E.V., J.F. Kirkpatrick, N.E. Schaffer, W.M. Bryant & W.R. Threlfall (1997). Serum and fecal steroid analysis of ovulation, pregnancy, and parturition in the Black Rhinoceros (*Diceros bicornis*). *Zoo Biology* 16(2): 121–132. [https://doi.org/10.1002/\(SICI\)1098-2361](https://doi.org/10.1002/(SICI)1098-2361)
- Ferawati, N.M., Z. Arsan, W.Y. Agvinta Nilam, S. Hasmaran & T. Roth (2018). Pengaruh keberadaan jaringan fibroid pada saluran reproduksi badak Sumatera betina terhadap potensi kebuntingannya [Effect of the presence of fibroid tissue on female reproductive track of the Sumatran rhino to the potential for pregnancy]. *Proceedings of the 20th FAVA Congress & 15th KIVNAS PDHI, Bali, Nov 1-3, 2018*: 322–324.
- Filkins, M.E. (1965). Congenital and heritable defects which interfere with the reproductive efficiency of domestic cattle (*Bos taurus*). *Iowa State University Veterinarian* 27(2): 67–75.
- Fiuza, R., R. Hermes, F. Goeritz, Z.Z. Zainuddin, P. Kretzschmar, J. Payne & T.B. Hildebrandt (2015). The Sabah Rhino Breeding Programme: reproductive pathology and its clinical implications in wild-caught Sumatran rhinoceroses. *Proceedings of the 10th International Conference on Behaviour, Physiology and Genetics of Wildlife*, Berlin: 70.
- Foose, T. (1999). *International Studbook for Sumatran Rhino (Dicerorhinus sumatrensis)*, 31 October 1999. International Rhino Foundation, Columbus, 12pp.
- Furley, C.W. (1993). The clinical history of the adult female Sumatran rhinoceros, called 'Subur' in captivity in Sumatra and at Port Lympne Zoo, Kent, Great Britain, pp. 357–366. In: Ryder, O.A. (ed.). *Rhinoceros Biology and Conservation: Proceedings of an International Conference*, San Diego, U.S.A. Zoological Society, San Diego (CA).
- Galli, C., R. Hermes, F. Goeritz, S. Colleoni, S. Diecke, M. Drukker, Katsuhiko Hayashi, S. Holtze, G. Lazzari, J. Payne, E. Sos, J. Stejskal, M. Wiesner, Z.Z. Zainuddin & T. Hildebrandt (2016). First results of oocyte maturation and in-vitro-fertilisation (IVF) in Sumatran and northern white rhinoceroses. *Proceedings of the Scientific program of the 15th International Elephant & Rhino conservation and research symposium*, Singapore, November 14–18, 2016: 51.
- Hermes, R. & T.B. Hildebrandt (2011). Rhinoceros theriogenology, pp. 546–561. In: *Fowler's Zoo and Wild Animal Medicine: Current Therapy*, vol. 7. Saunders, New York, 688 pp.
- Hermes, R., T.B. Hildebrandt & F. Goeritz (2004). Reproductive problems directly attributable to long-term captivity—asymmetric reproductive aging. *Animal Reproduction Science* 82–83: 49–60. <https://doi.org/10.1016/j.anireprosci.2004.05.015>
- Hermes, R., F. Goeritz, T.J. Portas, B.R. Bryant, J.M. Kelly, L.J. Maclellan, T. Keeley, F. Schwarzenberger, C. Walzer, A. Schnorrenberg, R.E. Spindler, J. Saragusty, S. Kaandorp & T.B. Hildebrandt (2009). Ovarian superstimulation, transrectal ultrasound-guided oocyte recovery, and IVF in rhinoceros. *Theriogenology* 72: 959–968. <https://doi.org/10.1016/j.theriogenology.2009.06.014>
- Hermes, R., F. Schwarzenberger, F. Goeritz, S. Oh, T. Fernandes, R. Bernardino, A. Leclerc, E. Greunz, A. Mathew, S. Forsyth, J. Saragusty & T.B. Hildebrandt (2016). Ovarian down regulation by GnRF vaccination decreases reproductive tract tumor size in female white and Greater One-horned Rhinoceroses (abstract). *Proceedings of the Scientific program of the 15th International Elephant & Rhino conservation and research symposium*, Singapore, November 14–18, 2016: 52.
- Hou, S.H., S. Grossman & M.E. Molitch (1985). Hyperprolactinemia in patients with renal insufficiency and chronic renal failure requiring hemodialysis or chronic ambulatory peritoneal dialysis. *American Journal of Kidney Diseases* 6(4): 245–249.
- Klein, L.V., R.A. Cook, P.P. Calle, B.L. Raphael & P. Thomas (1997). Etorphine-Isophlorine-O₂-anesthesia for ovariohysterectomy in an Indian rhinoceros (*Rhinoceros unicornis*), pp. 127–130. *Proceedings of the Annual Conference of the American Association of Zoo Veterinarians*, 26–30 October 1997, Houston, TX.
- Medikare, V., L.R. Kandukuri, V. Ananthapur, M. Deenadayal & P. Nallari (2011). The genetic bases of uterine fibroids: a review. *Journal of Reproduction & Infertility* 12(3): 181–191.
- Miller, P.S., C. Lees, W. Ramono, A. Purwoto, A. Rubianto, Sectionov, B. Talukdar (Eds.) (2015). *Population Viability Analysis for the Sumatran Rhino in Indonesia*. Apple Valley, MN: IUCN/SSC Conservation Breeding Specialist Group.
- Montali, R.J. & S.B. Citino (1993). Pathological findings in captive rhinoceroses, pp. 346–349. In: Ryder, O.A. (ed.). *Rhinoceros Biology and Conservation: Proceedings of an International Conference*, San Diego, U.S.A. Zoological Society, San Diego (CA).
- Morales, J.C., P.M. Andau, J. Supriatna, Z.Z. Zainuddin & D.J. Melnick (1997). Mitochondrial DNA variability and conservation genetics of the Sumatran rhinoceros. *Conservation Biology* 11(2): 539–543.
- Nardelli, F. (2014). The last chance for the Sumatran rhinoceros? *Pachyderm* 55: 43–53.
- Nardelli, F. (2019). Observations on the ex situ management of the Sumatran Rhinoceros *Dicerorhinus sumatrensis* (Mammalia: Perissodactyla: Rhinocerotidae): present status and desiderata for conservation. *Journal of Threatened Taxa* 11(15): 14927–14941. <https://doi.org/10.11609/jott.4952.11.15.14927-14941>
- Parazzini, F., C. La Vecchia, E. Negri, G. Cecchetti & L. Fedele (1988). Epidemiologic characteristics of women with uterine fibroids: a case-control study. *Obstetrics & Gynecology* 72: 853–857.
- Payne, J. & K. Yoganand (2018). *Critically Endangered Sumatran Rhinoceros: Inputs for Recovery Strategy and Emergency Actions 2017-2027*. WWF Indonesia, Jakarta, 114 pp.
- Radcliffe, R. (2003). *Reproduction and health assessments 2001-2003*. Sumatran Rhino Conservation Centre, Sungai Dusun, Malaysia.
- Radcliffe, R.M., D.A. Hendrickson, G.L. Richardson, J.R. Zuba & R.W. Radcliffe (2000). Standing laparoscopic-guided uterine biopsy in a Southern White Rhinoceros (*Ceratotherium simum simum*). *Journal of Zoo and Wildlife Medicine* 31: 201–207. <https://doi.org/10.1638/1042-7260>
- Roth, T.L. (2006). A review of the reproductive physiology of rhinoceros species in captivity. *International Zoo Yearbook* 40: 130–143. <https://doi.org/10.1111/j.1748-1090.2006.00130.x>
- Roth, T.L., J.K. O'Brien, M.A. McRae, A.C. Bellem, S.J. Romo, J.L. Kroll & J.L. Brown (2001). Ultrasound and endocrine evaluation of the ovarian cycle and early pregnancy in the Sumatran Rhinoceros,

- Dicerorhinus sumatrensis*. *Reproduction* 121: 139–149. <https://doi.org/10.1530/rep.0.1210139>
- Roth, T.L., H.L. Bateman, J.L. Kroll, B.G. Steinmetz & P.R. Reinhart (2004). Endocrine and ultrasonographic characterization of a successful pregnancy in a Sumatran Rhinoceros (*Dicerorhinus sumatrensis*) supplemented with a synthetic progestin. *Zoo Biology* 23: 219–238. <https://doi.org/10.1002/zoo.10131>
- Roth, T.L., M.W. Schook & M.R. Stoops (2018). Monitoring and controlling ovarian function in the rhinoceros. *Theriogenology* 109: 48–57; <https://doi.org/10.1016/j.theriogenology.2017.12.007>
- Saragusty, J., S. Diecke, M. Drukker, B. Durrant, I.F. Ben-Nun, C. Galli, F. Goeritz, K. Hayashi, R. Hermes, S. Holtze, S. Johnson, G. Lazzari, P. Loi, J.F. Loring, K. Okita, M.B. Renfree, S. Seet, T. Voracek, J. Stejskal, O.A. Ryder & T.B. Hildebrandt (2016). Rewinding the process of mammalian extinction. *Zoo Biology* 35(4): 280–292. <https://doi.org/10.1002/zoo.21284>
- Schaffer, N.E. (2018). Sumatran rhinoceros: reproductive data 1991–1999, with updates and addenda to 2018. SOS Rhino, Washington (DC), 78pp. Available from: http://www.rhinosourcecenter.com/index.php?s=1&act=refs&CODE=ref_detail&id=1537427226.
- Schaffer, N.E., M. Agil & E. Bosi (2001). Utero-ovarian pathological complex of the Sumatran rhinoceros (*Dicerorhinus sumatrensis*), p.322. In: Schwammer, H.M. (ed.). Recent Research on Elephants and Rhinos: Abstracts of The International Elephant and Rhino Research Symposium, June 7–11, 2001. Zoologischer Garten, Vienna.
- Schaffer, N.E., W. Bryant, E. Berkeley, J.A. Berry, R. Powell, C. Barnett & J. Joyce (1995). Case Report: successful birth after intensive management of an aged Black Rhinoceros (*Diceros bicornis*) with a history of abortions. Proceedings of the Regional Conference Proceedings of the AZA, 1995: 332–337.
- Schaffer, N.E., Z.Z. Zainuddin, M.S.M. Suri, M.R. Jainudeen & R.S. Jeyendran (1994). Ultrasonography of the reproductive anatomy in the Sumatran Rhinoceros (*Dicerorhinus sumatrensis*). *Journal of Zoo and Wildlife Medicine* 25(3): 337–348.
- Tibary, A. (2016). [Internet]. Female genital abnormalities. Merck Veterinary Manual Online. Electronic version accessed 9 April 2019.
- Wolfsdorf, K.E. (2002). Endometrial cysts. *Proceedings of the Bluegrass Equine Reproduction Symposium*, Lexington, Ky. (without pages).

Bahasa Indonesia Abstrak: Badak Sumatera *Dicerorhinus sumatrensis* berada di ujung kepunahan. Penurunan spesies ini pada awalnya dikaitkan dengan perburuan liar dan hilangnya habitat, tetapi bukti yang disajikan di sini menunjukkan bahwa kegagalan reproduksi juga telah menjadi penyebab utama hilangnya, dan terus mempengaruhi penurunan populasi liar. Populasi badak Sumatera yang tersisa di Indonesia adalah kecil dan tersebar, dengan akses terbatas ke peluang berkembang biak dengan pasangan yang tidak berkerabat. Kondisi tersebut mengakibatkan terjadinya inbreeding dan mengakibatkan infertilitas-akibat terisolasi, berhubungan dengan masalah kesuburan yang dianalisis dalam tulisan ini. Betina badak Sumatera di penangkaran menunjukkan tingkat patologi reproduksi dan / atau masalah dengan konsepsi yang tinggi (> 70%) yang secara signifikan menghambat program pengembangbiakannya. Kemajuan teknologi memungkinkan pemeriksaan segera setelah penangkaran dan menunjukkan tingkat dan jenis masalah reproduksi yang sama tingginya pada individu dari populasi liar. Tujuh Badak Sumatera betina yang terakhir ditangkap berasal dari daerah dengan populasi kecil yang menurun, dan ditemukan enam badak memiliki masalah reproduksi. Badak-badak yang tidak reproduktif selanjutnya akan mengambil ruang berharga dan sumber daya yang dibutuhkan untuk hewan subur. Risiko tinggi infertilitas dan kesulitan mengobati penyebabnya, ditambah dengan terus menurunnya jumlah badak yang tersisa di alam, maka keberhasilan upaya untuk membangun populasi badak dipenangkaran yang layak akan sangat tergantung pada pemanfaatan hewan subur dan penerapan teknik reproduksi berbantuan. Survei in situ yang lengkap dalam beberapa dasawarsa belum memberikan informasi yang relevan dengan manajemen populasi atau untuk memastikan status kesuburan masing-masing hewan. Dengan demikian Prioritas pertama dalam penyelamatan badak di alam adalah penangkapan individu sebagai sumber darah baru dari daerah dengan kemungkinan tertinggi mengandung badak subur, ditunjukkan oleh foto dari badak betina dengan anak-anaknya dari perangkat kamera yang baru-baru ini ditemukan. Daerah tersebut termasuk Way Kambas dan bagian ekosistem Leuser untuk saat ini di wilayah Sumatera.

Author details: NAN SCHAFFER'S (M.S., D.V.M.), seminal work on reproduction of rhinoceroses, since her residency at the Bronx Zoo in 1981, resulted in the first extraction of semen with electroejaculation and the first ultrasound of the female reproductive tract. She was the first to identify the high prevalence of reproductive pathology in female Sumatran Rhino, which she has reported on since 1991. MUHAMMAD AGIL (M.Sc. Agr., D.V.M., Dipl. A.C.C.M.) is a senior lecturer and researcher at the Faculty of Veterinary Medicine, IPB University. He has studied the reproductive biology and conservation needs of the Sumatran Rhino since 1993. His work and research interests also include the Javan Rhino, Banteng and Sumatran Elephant. ZAINAL ZAINUDDIN (D.V.M.) is a wildlife veterinarian who was involved with Sumatran Rhino capture, captive management, and assisted reproductive technologies in Malaysia and Indonesia. Since his work began in 1985, he has handled the veterinary care and pathological analysis of over 20 individual rhinos. He has over 20 publications on this species.

Author contribution: This paper represents decades of collaborative field work and research among these three colleagues in their shared mission to recover the Sumatran Rhino genus. N. Schaffer compiled the data and wrote the manuscript. All authors reviewed and approved the final manuscript.





PLATINUM
OPEN ACCESS



The Journal of Threatened Taxa (JoTT) is dedicated to building evidence for conservation globally by publishing peer-reviewed articles online every month at a reasonably rapid rate at www.threatenedtaxa.org. All articles published in JoTT are registered under [Creative Commons Attribution 4.0 International License](https://creativecommons.org/licenses/by/4.0/) unless otherwise mentioned. JoTT allows unrestricted use, reproduction, and distribution of articles in any medium by providing adequate credit to the author(s) and the source of publication.

ISSN 0974-7907 (Online) | ISSN 0974-7893 (Print)

February 2020 | Vol. 12 | No. 3 | Pages: 15279–15406

Date of Publication: 26 February 2020 (Online & Print)

DOI: 10.11609/jott.2020.12.3.15279-15406

www.threatenedtaxa.org

Review

Ramifications of reproductive diseases on the recovery of the Sumatran Rhinoceros *Dicerorhinus sumatrensis* (Mammalia: Perissodactyla: Rhinocerotidae)

– Nan E. Schaffer, Muhammad Agil & Zainal Z. Zainuddin, Pp. 15279–15288

Communications

Diet ecology of tigers and leopards in Chhattisgarh, central India

– Krishnendu Basak, Moiz Ahmed, M. Suraj, B.V. Reddy, O.P. Yadav & Krishnendu Mondal, Pp. 15289–15300

Building walls around open wells prevent Asiatic Lion *Panthera leo persica* (Mammalia: Carnivora: Felidae) mortality in the Gir Lion Landscape, Gujarat, India

– Tithi Kagathara & Erach Bharucha, Pp. 15301–15310

Taxonomic and ecological notes on some poorly known bats (Mammalia: Chiroptera) from Meghalaya, India

– Uttam Saikia, AdoraThabab & Manuel Ruedi, Pp. 15311–15325

Angiosperm diversity in Bhadrak region of Odisha, India

– Taranisen Panda, Bikram Kumar Pradhan, Rabindra Kumar Mishra, Srusti Dhar Rout & Raj Ballav Mohanty, Pp. 15326–15354

Short Communications

Sighting of *Petaurista petaurista* (Pallas, 1766) (Mammalia: Rodentia: Sciuridae) on limestone hills in Merapoh, Malaysia

– Priscillia Miard, Mohd Nur Arifuddin, Izereen Mukri, Siti Syuhada Sapno, Hafiz Yazid, Nadine Ruppert & Jayaraj Vijaya Kumaran, Pp. 15355–15358

Molecular detection of *Murshidia linstowi* in a free-ranging dead elephant calf

– Sourabh Ranjan Hota, Sonali Sahoo, Manojita Dash, Avisek Pahari, Bijayendranath Mohanty & Niranjana Sahoo, Pp. 15359–15363

Parasite commonality at Swamp Deer (Mammalia: Artiodactyla: Cervidae: *Rucervus duvaucelii duvaucelii*) and livestock interface

– Animesh Talukdar, Bivash Pandav & Parag Nigam, Pp. 15364–15369

Prevalence and seasonal variation of gastrointestinal parasites among captive Northern Pig-tailed Macaque *Macaca leonina* (Mammalia: Primates: Cercopithecidae)

– Phoebe Lalremruati & G.S. Solanki, Pp. 15370–15374

New record of *Tulostoma squamosum* (Agaricales: Basidiomycota) from India based on morphological features and phylogenetic analysis

– Arun Kumar Dutta, Soumitra Paloi & Krishnendu Acharya, Pp. 15375–15381

Notes

An account of a first record of the Common Goldeneye

***Bucephala clangula* Linnaeus, 1758 (Aves: Anseriformes: Anatidae) in Bhutan**

– Sangay Nidup, Gyeltshen & Tshering Tobgay, Pp. 15382–15384

First record of the hawkmoth *Theretra lyctetus* (Cramer, 1775) (Sphingidae: Macroglossinae) from Bhutan

– Sangay Nidup & Jatishwor Singh Irungbam, Pp. 15385–15386

Occurrence and association of the Scarce Lilacfork

***Lethe dura gammiei* (Moore, [1892]) (Lepidoptera: Nymphalidae: Satyrinae) with Woolly-leaved Oak *Quercus lanata* Smith, 1819 (Fabaceae) forest in the Kumaon region of the Indian Himalaya**

– Arun P. Singh & Tribhuwan Singh, Pp. 15387–15390

Additions to the Odonata (Insecta) fauna of Asansol-Durgapur Industrial Area, West Bengal, India

– Amar Kumar Nayak, Pp. 15391–15394

***Gynochthodes cochinchinensis* (DC.) Razafim. & B. Bremer (Morindeae: Rubioideae: Rubiaceae): an addition to the woody climbers of India**

– Pradeep Kumar Kamila, Prabhat Kumar Das, Madhusmita Mallia, Chinnamadasamy Kalidass, Jagayandatt Pati & Pratap Chandra Panda, Pp. 15395–15399

Record of *Oldenlandia hygrophila Bremek.* (Spermacoaceae: Rubiaceae), a lesser known herb from Palghat Gap of Western Ghats, Kerala, India

– Vadakkeveedu Jagadesh Aswani, Vasudevan Ambat Rekha, Pathiyil Arabhi, Manjakulam Khadhersha Jabeena, Kunnamkumarath Jisha & Maya Chandrashekar Nair, Pp. 15400–15404

Book Review

The State of Wildlife and Protected Areas in Maharashtra: News and Information from the Protected Area Update 1996-2015

– Reviewed by L.A.K. Singh, Pp. 15405–15406

Member



Publisher & Host

